



## Maryland Chapter

# AMERICAN COLLEGE OF EMERGENCY PHYSICIANS

## Maryland ACEP Chapter Educational Conference & Annual Meeting March 12, 2020

**FACULTY:** [Eric R. Friedman, MD](#)

### PRESENTATION

The State of the Nonunion

### DESCRIPTION

This presentation will discuss commonly mismanaged orthopedic injuries in the emergency department. You will learn to be comfortable with multiple different ankle injuries. Be knowledgeable about knee injuries and how to perform a femoral nerve block.

### OBJECTIVES

- **High ankle sprains:** the different ligaments that get injured, XRAY findings, and management
- **Fibula fractures:** Weber criteria
- **ACL tears:** Different PE maneuverers to evaluate
- **Knee dislocation and management**
- **Management of a commonly missed wrist injury:** Hook of hamate fx and diagnosis

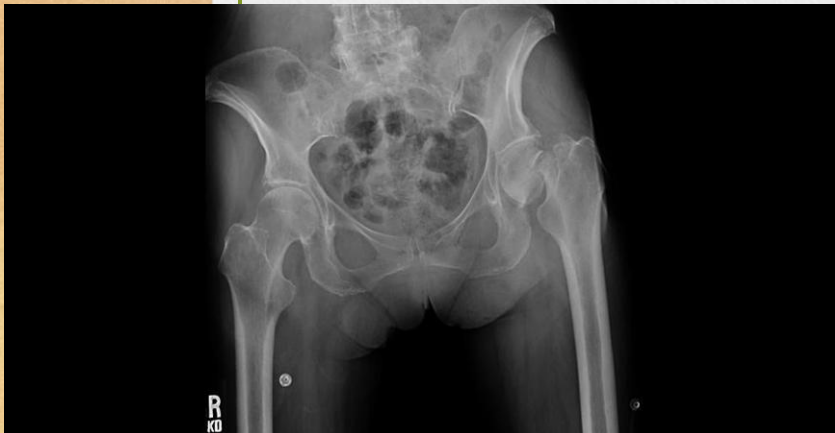### DISCLOSURE

No significant financial relationships to disclose.

# The State of the Nonunion

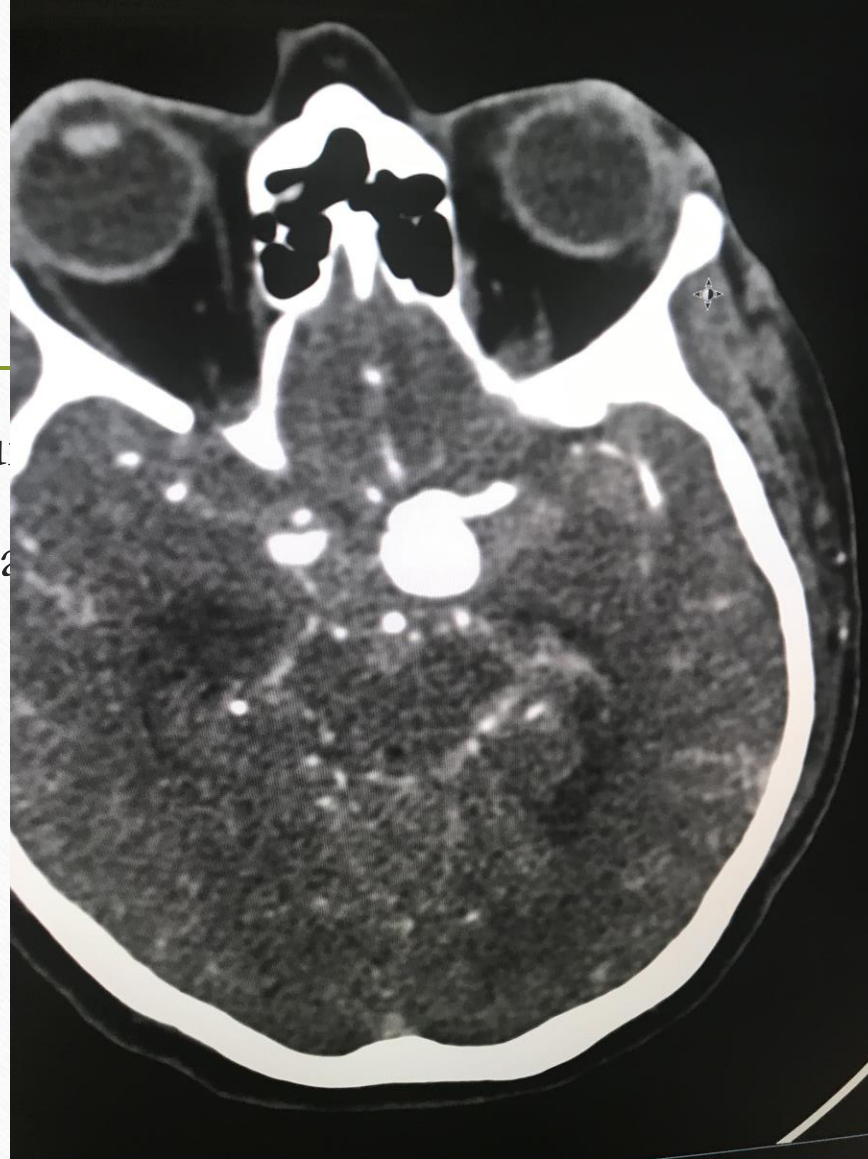By

Eric Friedman



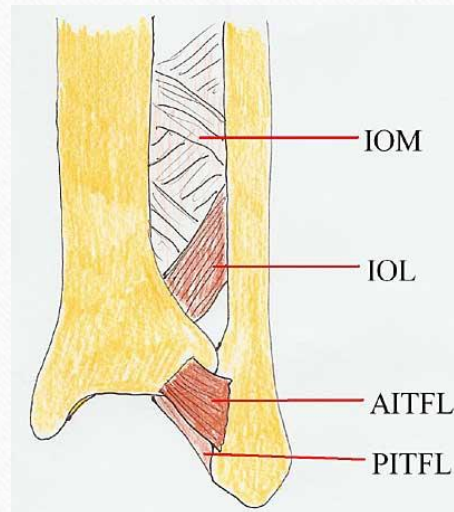


- 206 bones in the hu
- All of them are capa

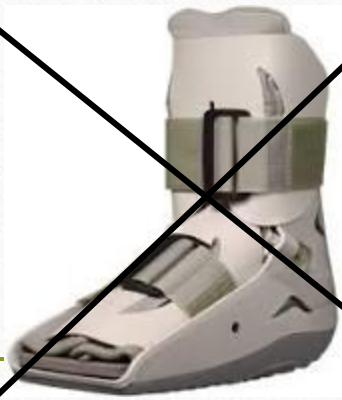

# High Ankle Sprain

- 25k ankle sprain per day in EDs (including low ankle sprain)

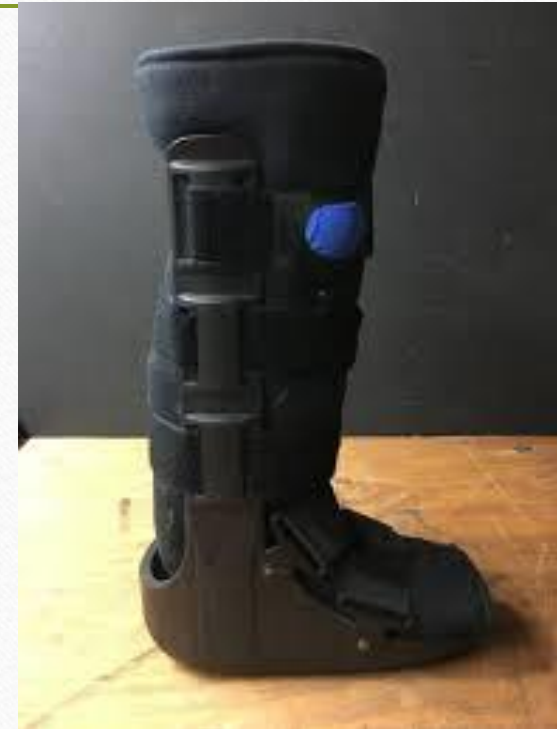


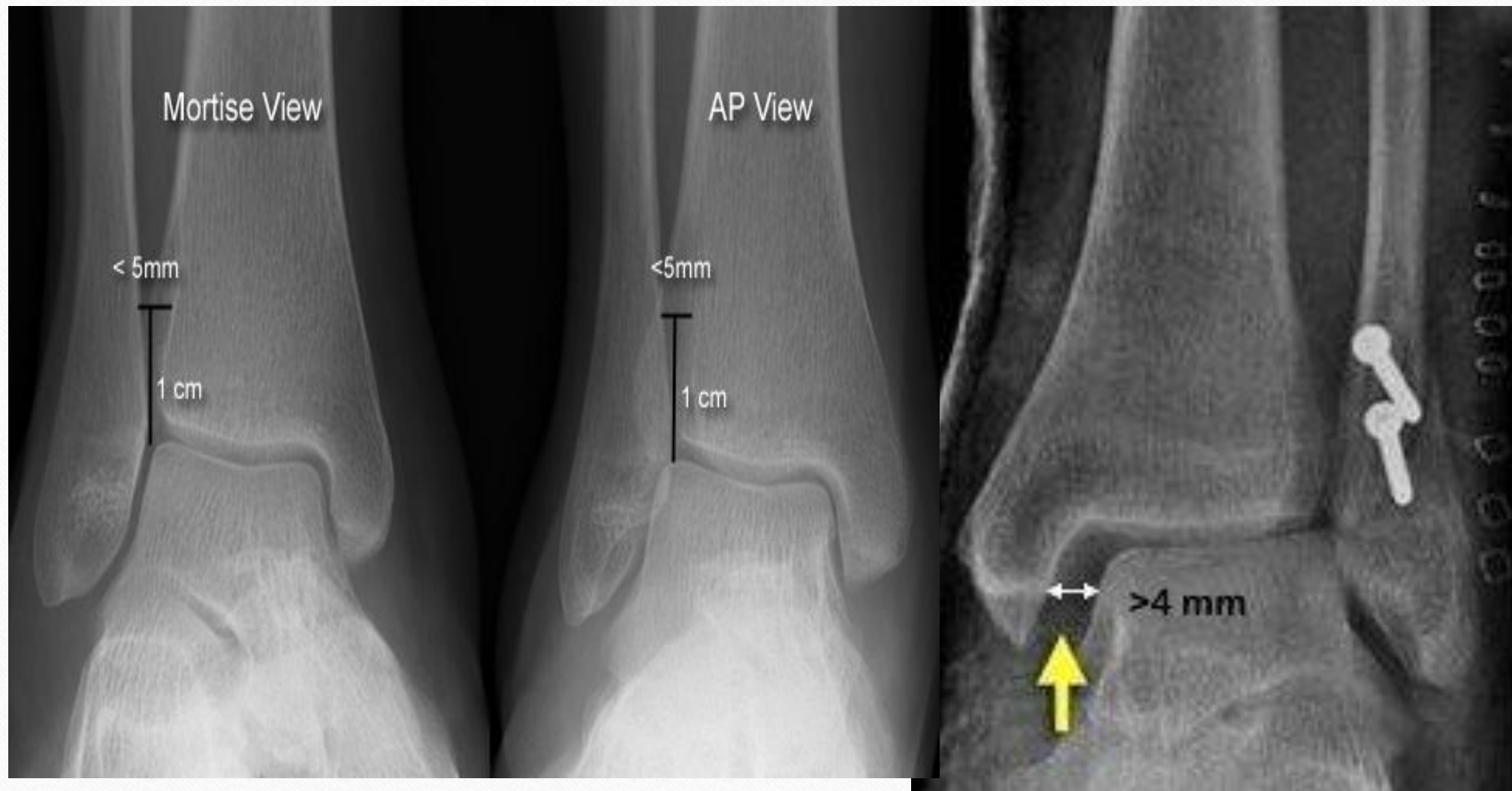


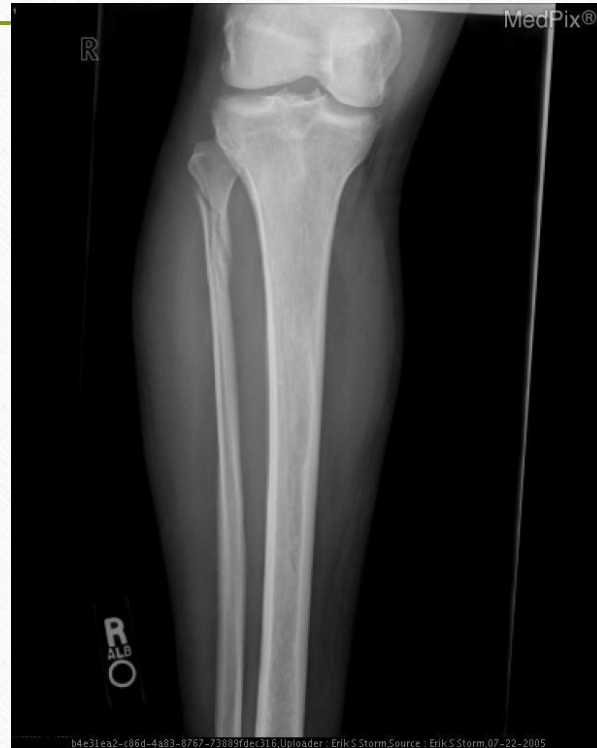# High Ankle Sprains

- Syndesmotic membrane injury
- Symptoms
  - Anterolateral ankle pain proximal to AITFL
  - May have medial sided ankle tenderness/swelling
  - More difficulty bearing weight than normal lateral ankle sprains
- Physical Exam
  - Syndesmosis Tenderness (best predictor of return to play)
  - Squeeze Test





# Maisonneuve Fracture






# Case

- Volleyball player landed and rolled ankle
- TTP of lateral malleolus
- XRAY: Fibular Fracture





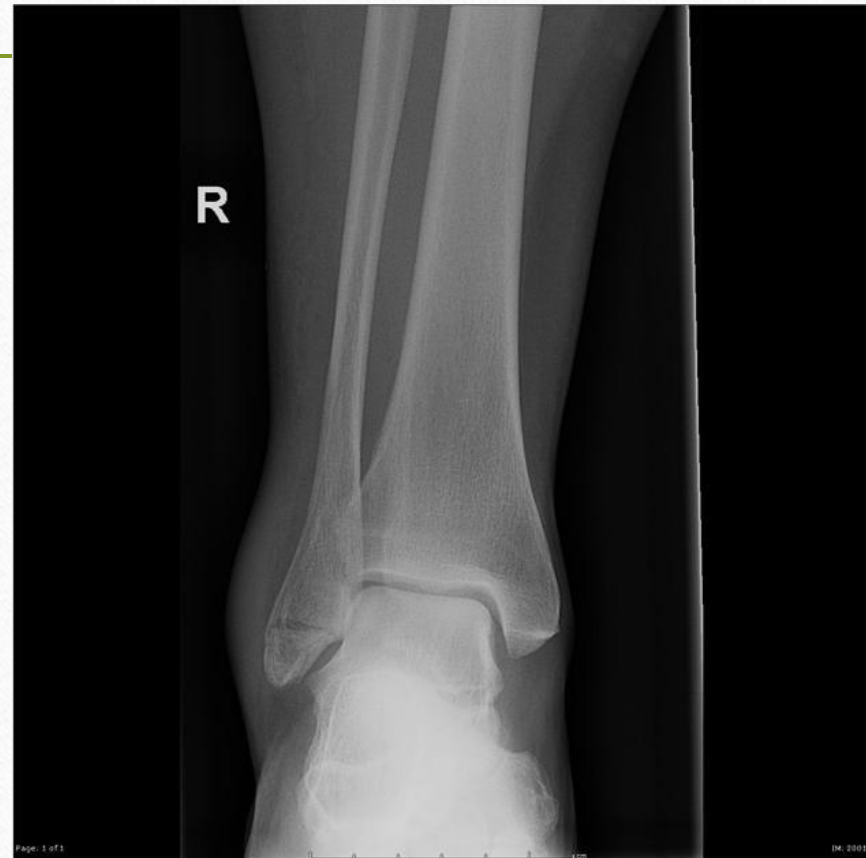# Weber Criteria



- Isolated distal fibular fractures
- Weber A: below the level of the syndesmosis
- Weber B at level of the syndesmosis, need stress view to determine stability
- Weber C: above the level of the syndesmosis, unstable
- Any bimalleolar (or trimalleolar) fracture is unstable

# Weber A

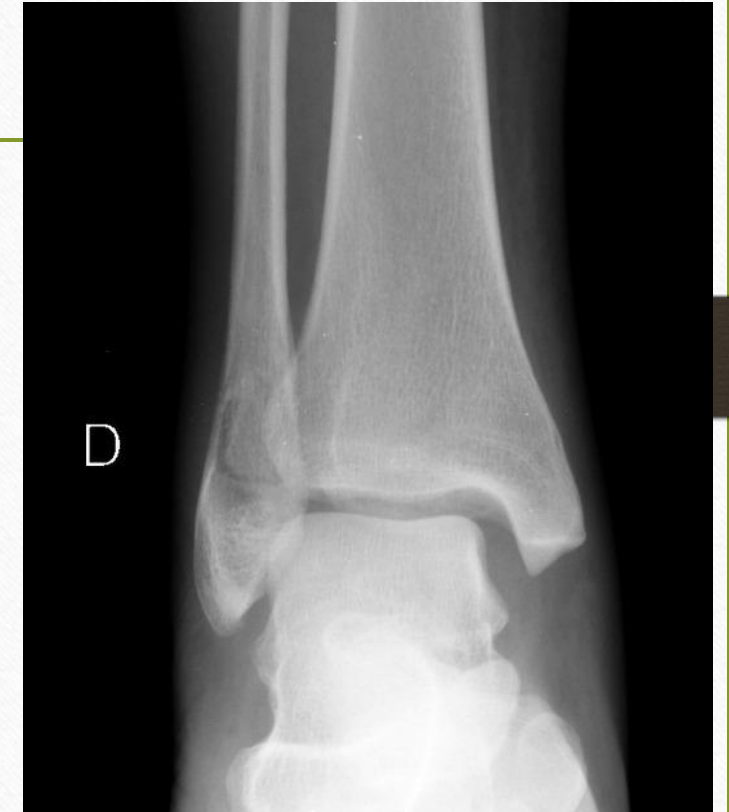- Non-op
- Stable





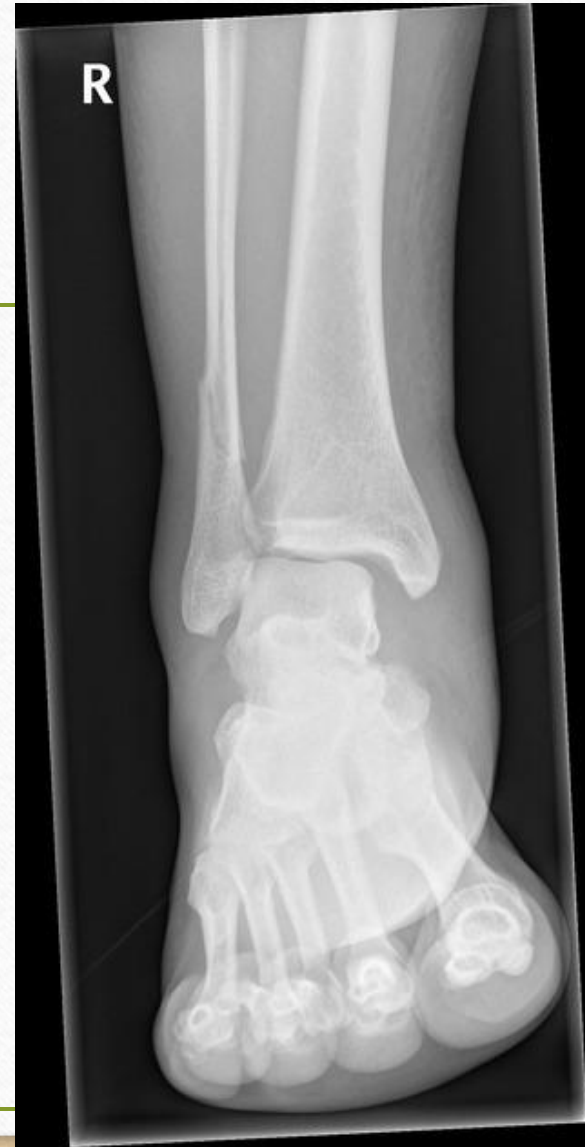# Weber B

- Need to do a stress view and look for medial widening
- >4-5 mm of medial clear space widening → surgery



# Weber C


- Unstable and needs surgery



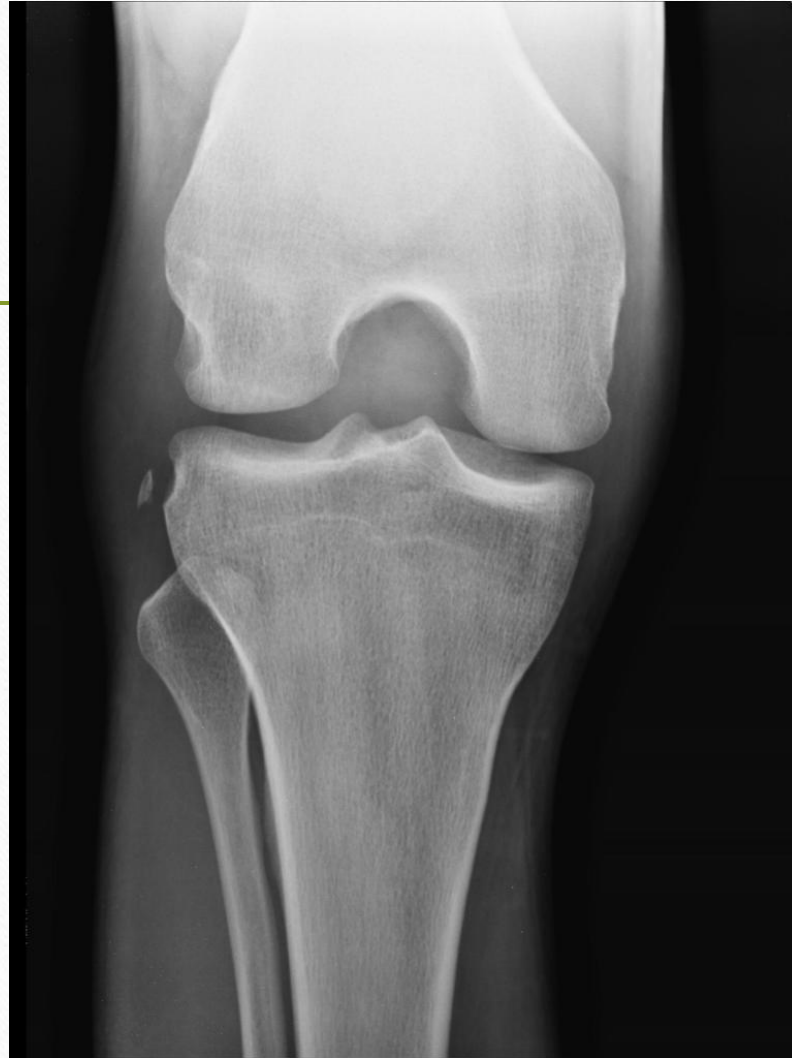

# Case

- 25 yo M presents with right knee pain
- He planted and twisted to cut and felt pain
- Exam: rt knee edema



- 
- Segund Fracture
  - Fracture of the lateral tibial condyle of the knee





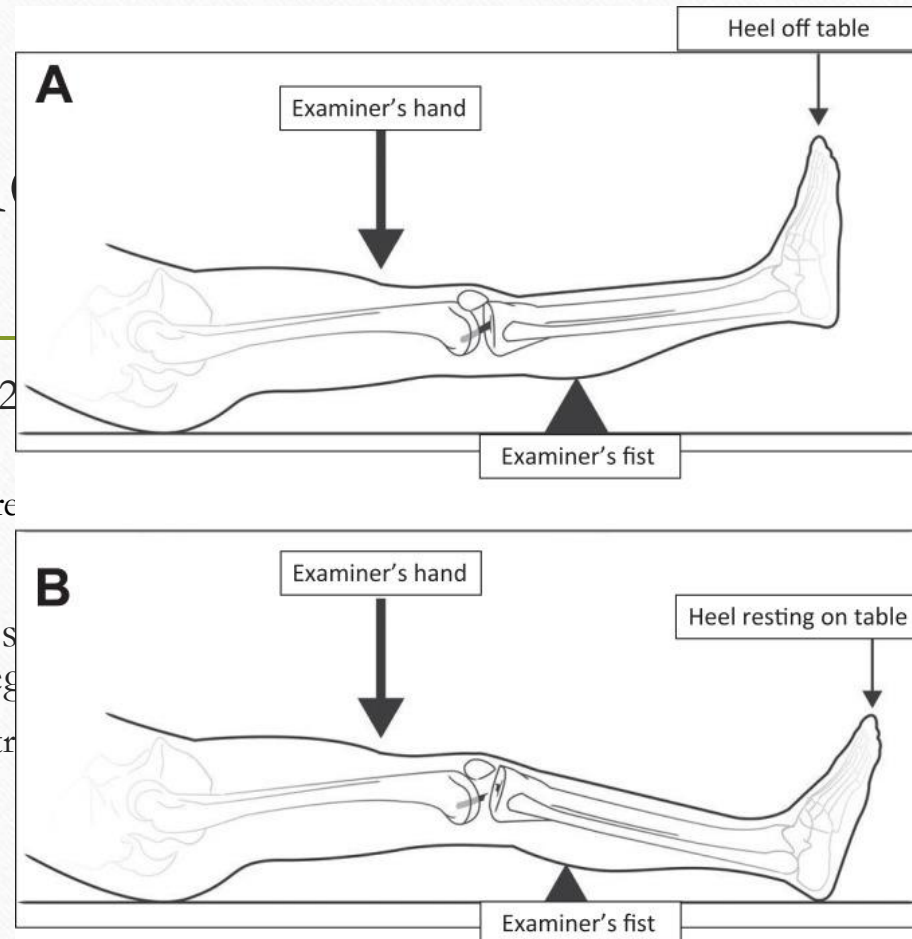
# ACL tears

---

- Acute hemarthrosis
- More common in females
- ACL is the most commonly injured ligament in the body for which surgery is frequently performed
- MCL is most common ligament torn
- Usually noncontact when cutting and pivoting

# Physi

- Lachman test: Place the patient's knee in about 20 degrees of flexion, and translate the lower leg.
  - Positive test: >2mm of anterior translation compared to the other knee
  - Sensitivity: ~84% Specificity: ~94%
- Anterior Drawer test: knees flexed to 90 degrees, and translate the lower leg.
  - Positive test: lack of end feel or excessive anterior translation
  - Sensitivity: ~73% Specificity: 93%
- Lelli test/Lever sign
  - Sensitivity: 100% Specificity 100%
  - Repeat study Sensitivity: 63% Specificity 90% (worse than Lachman and anterior drawer in study)



translate

the



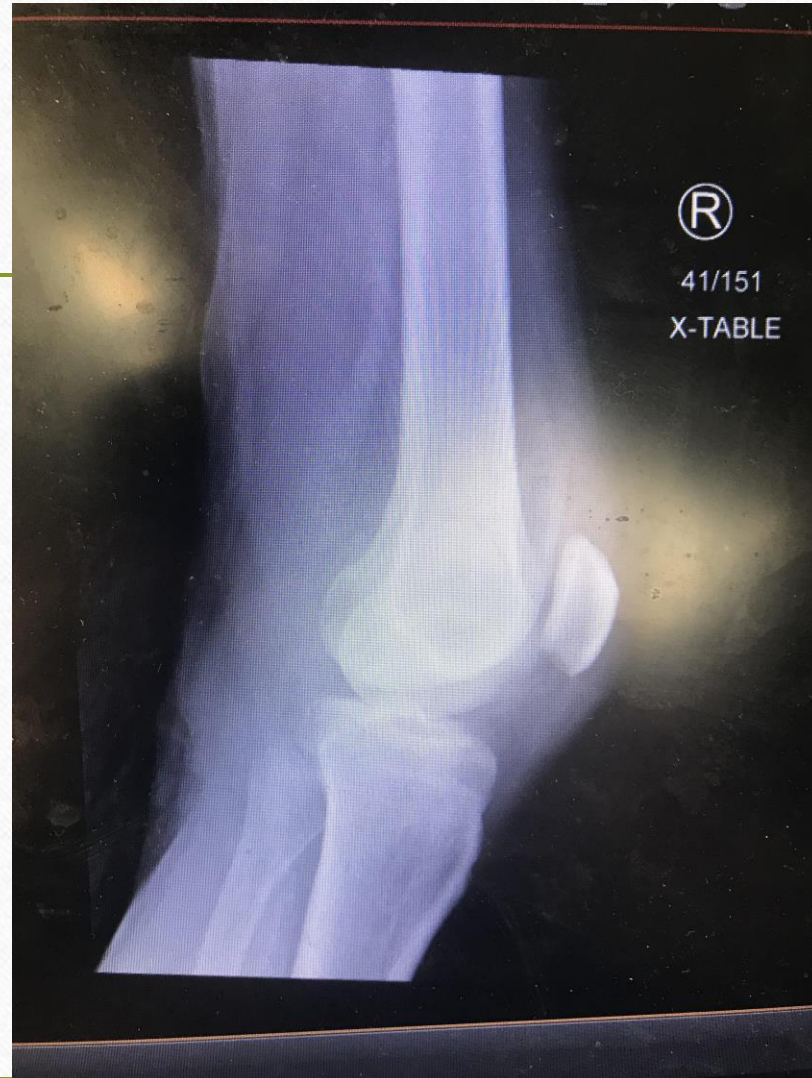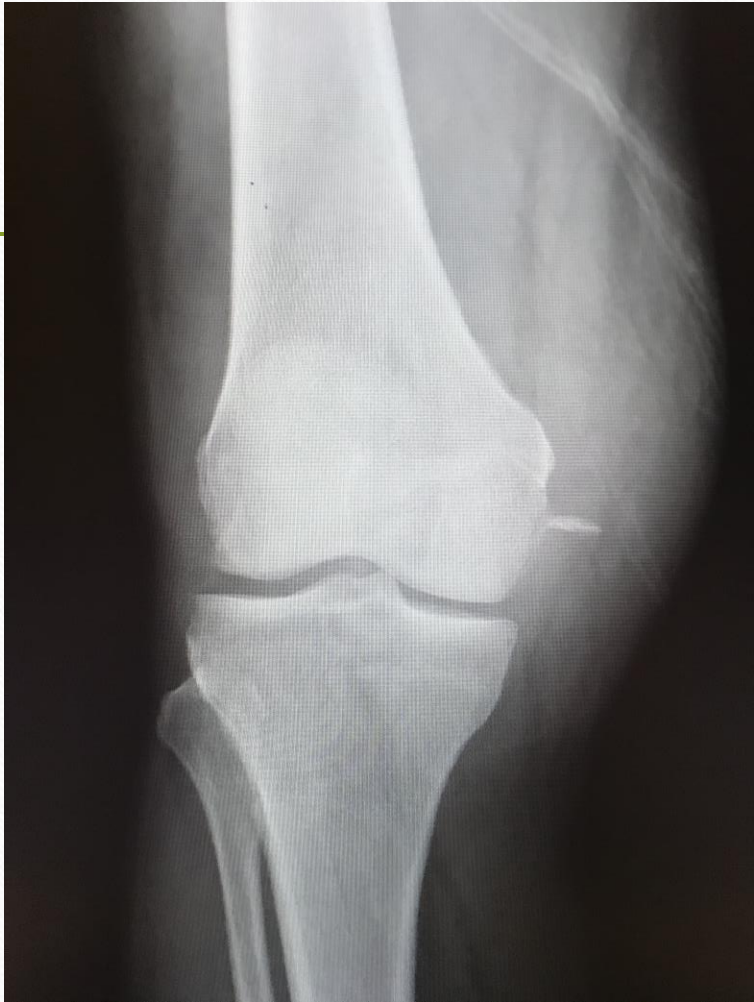# Why Does All This Matter in the ED?

---

# Another Case



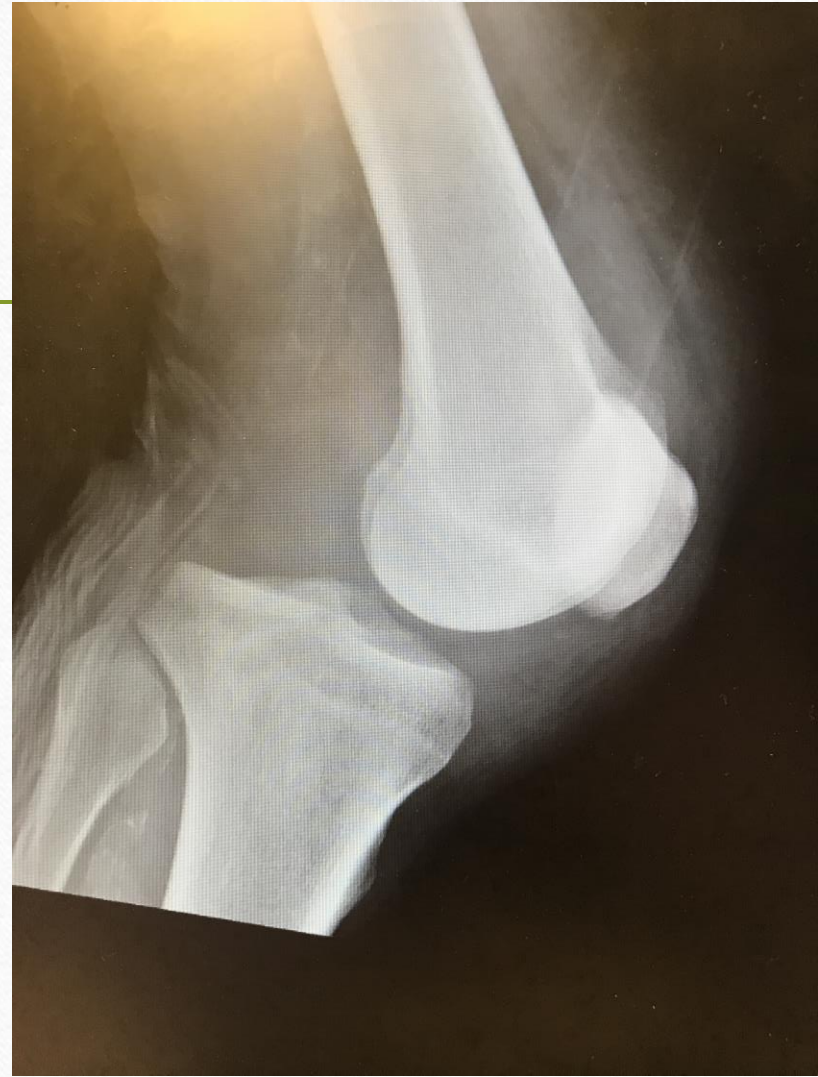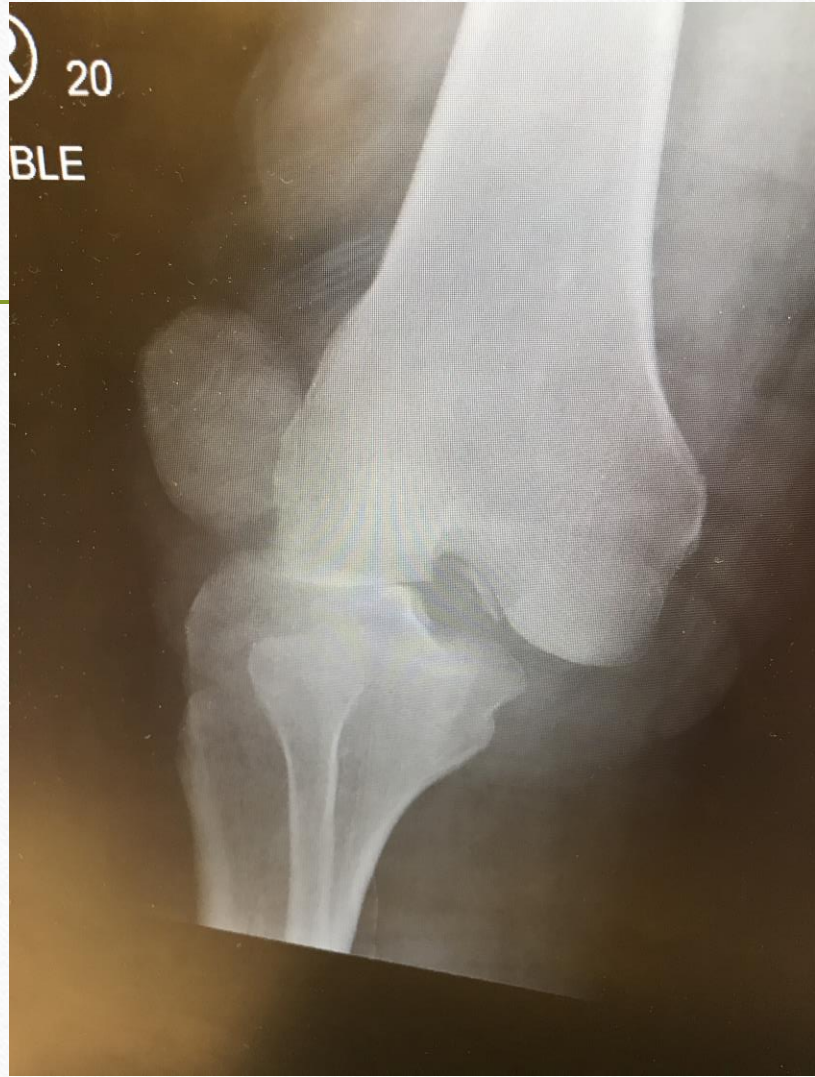


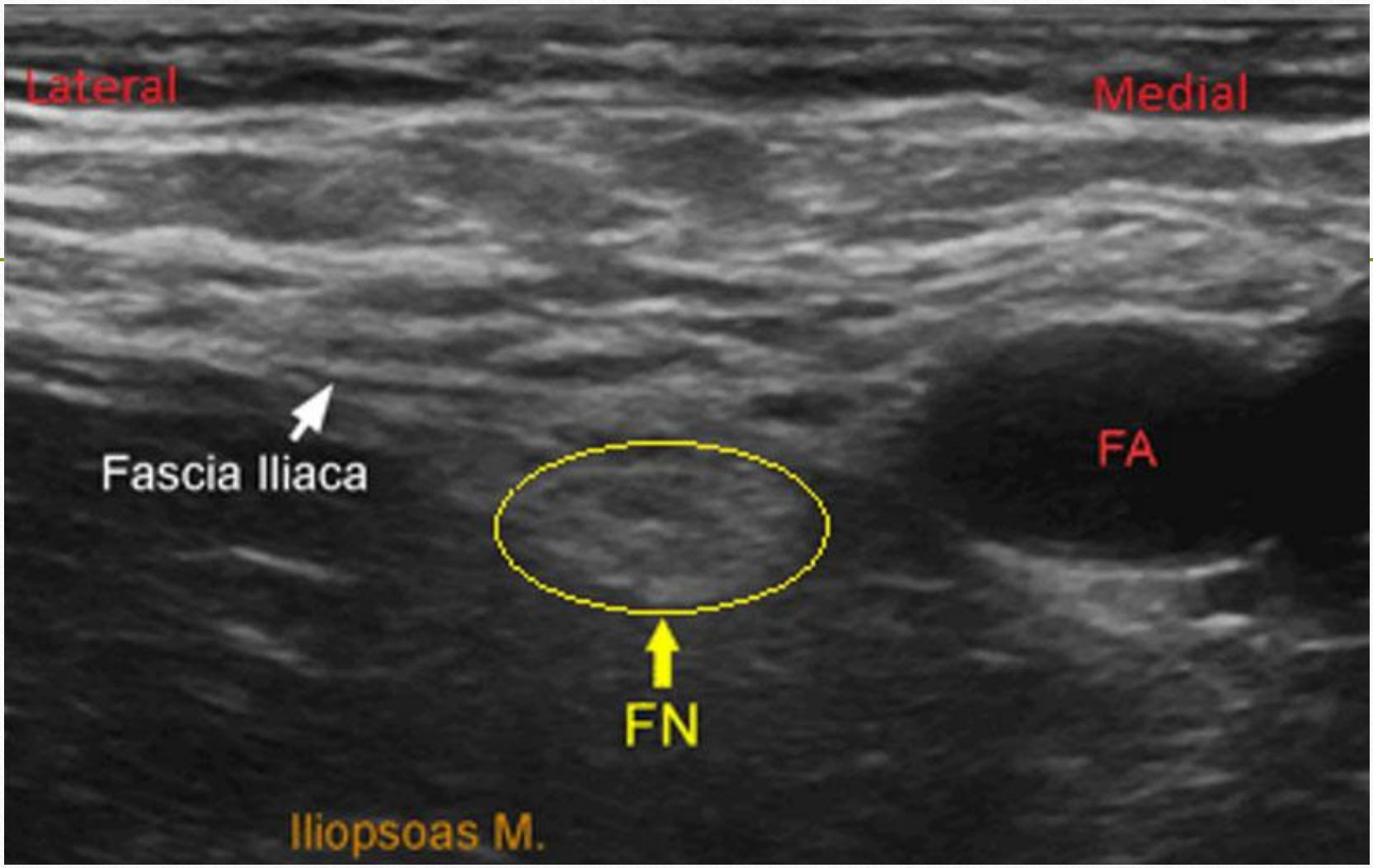


# Nurse Calls



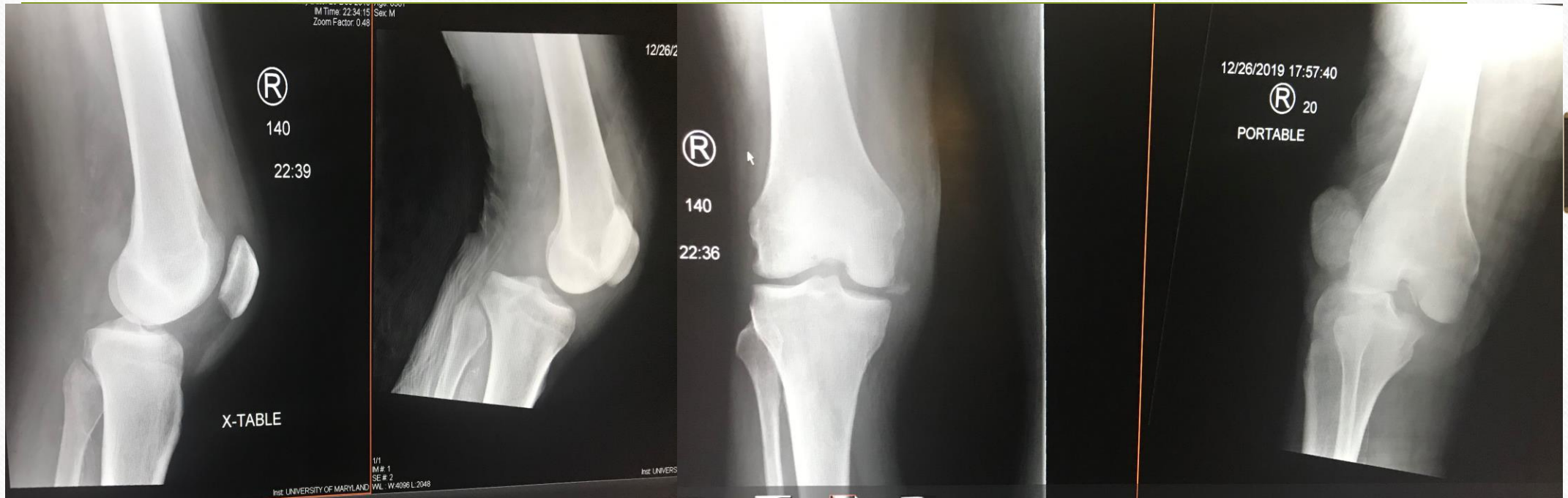







# Relocated



# Another Case

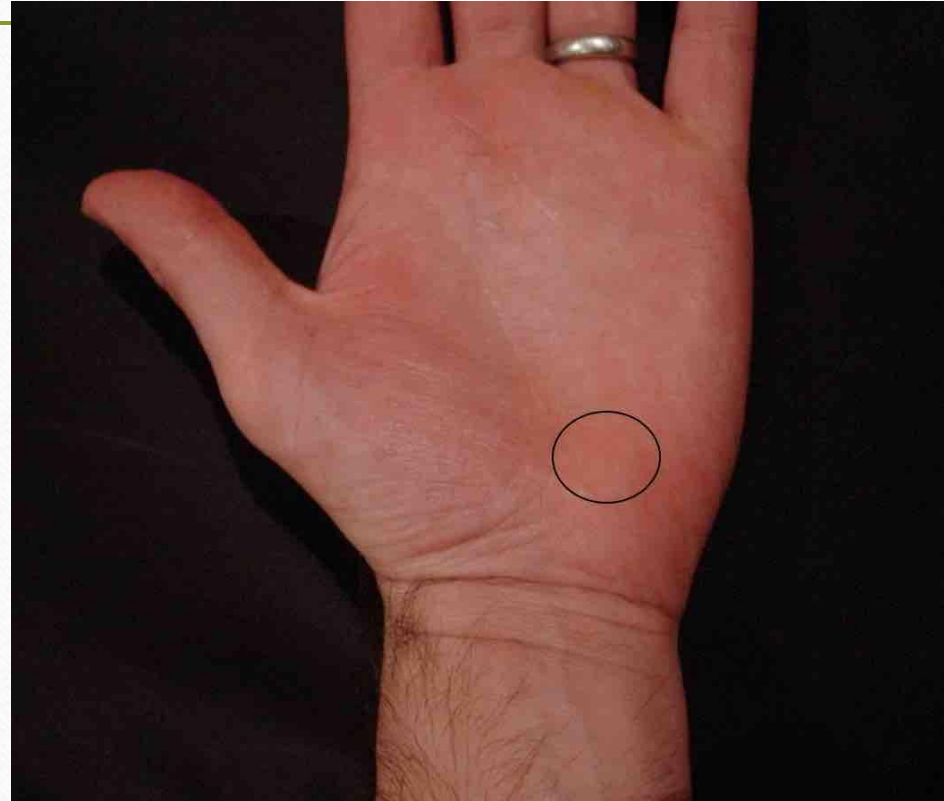
---

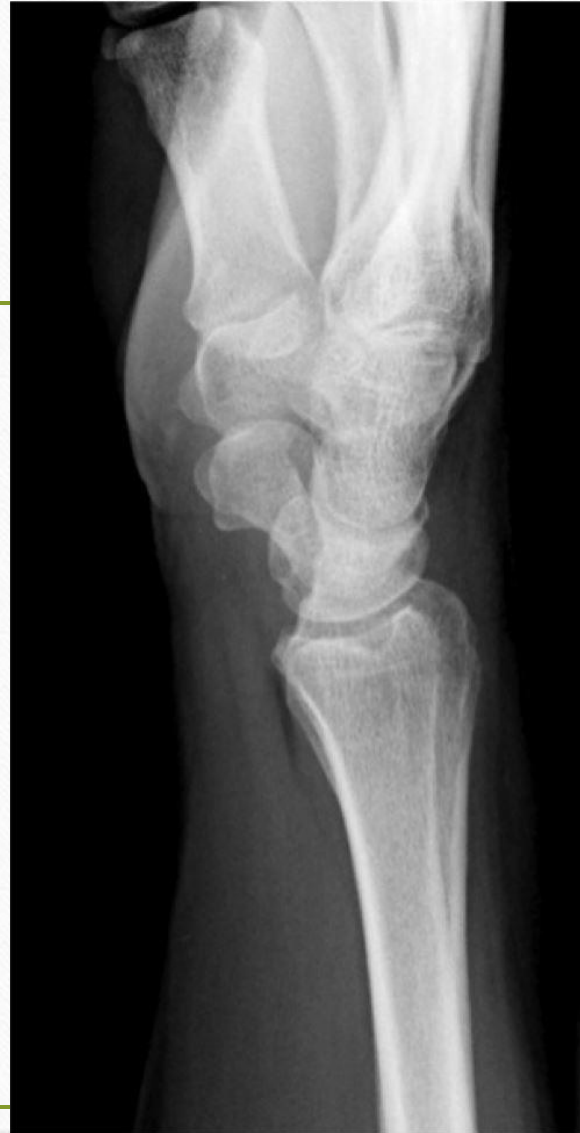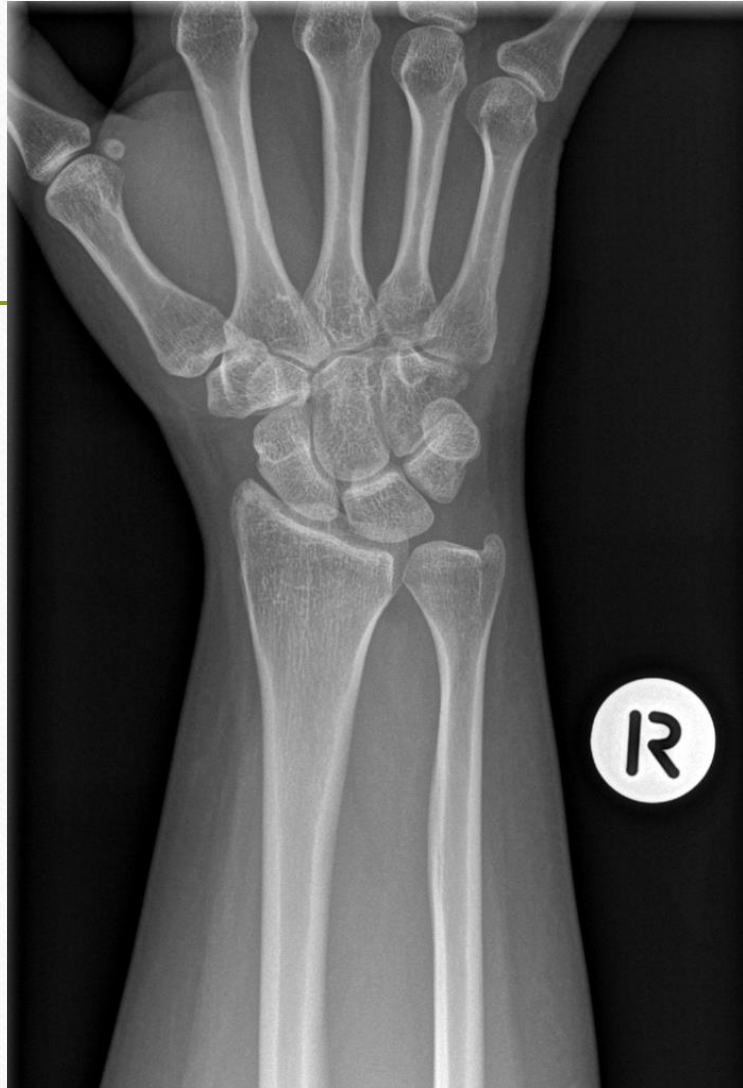- Golfer with rt. wrist pain



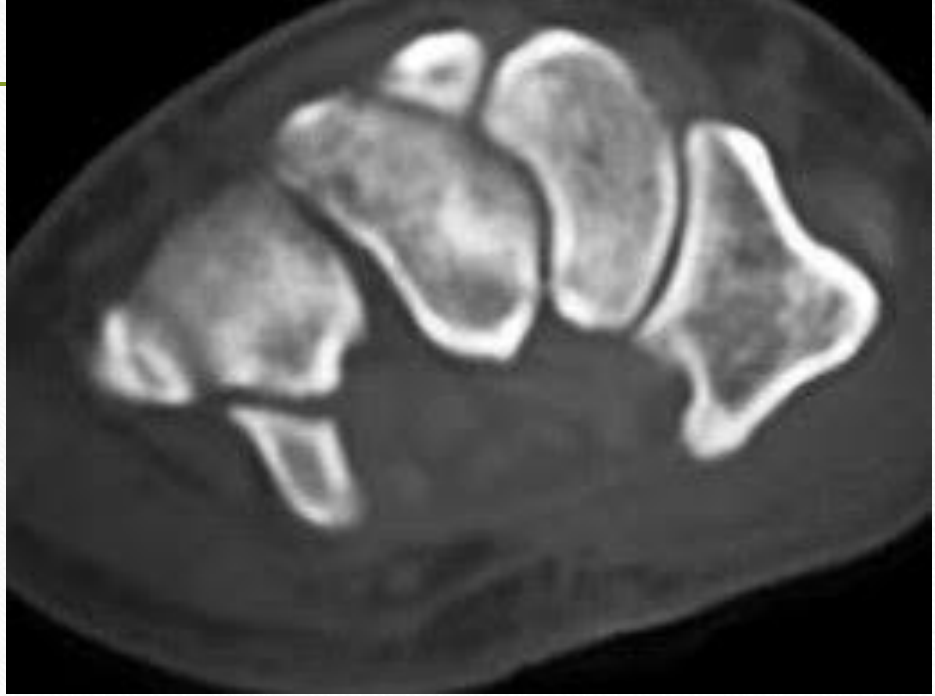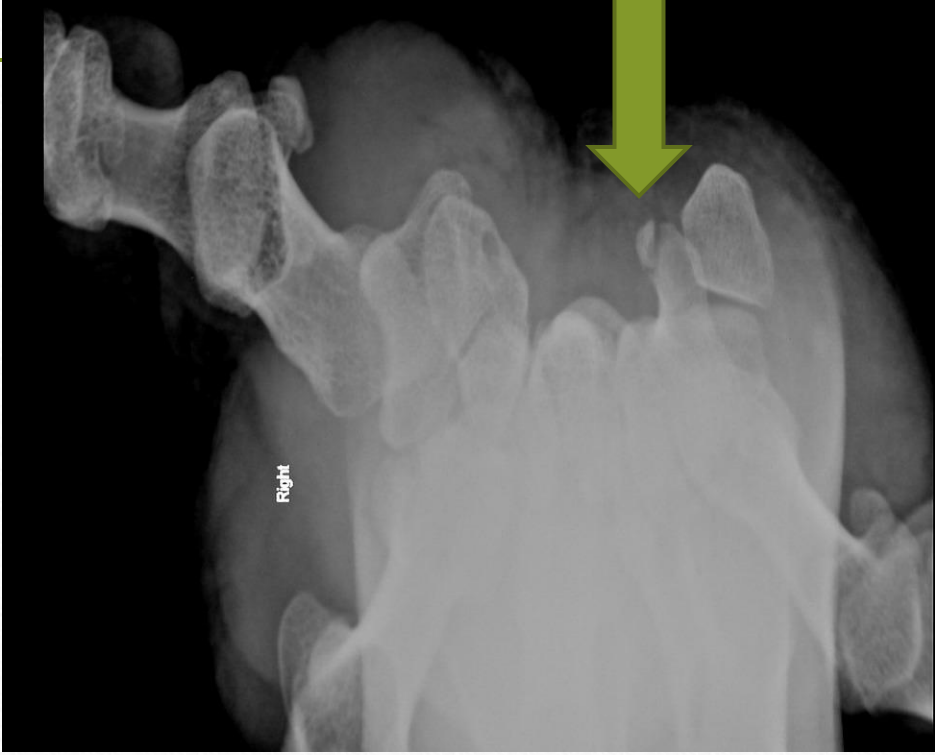


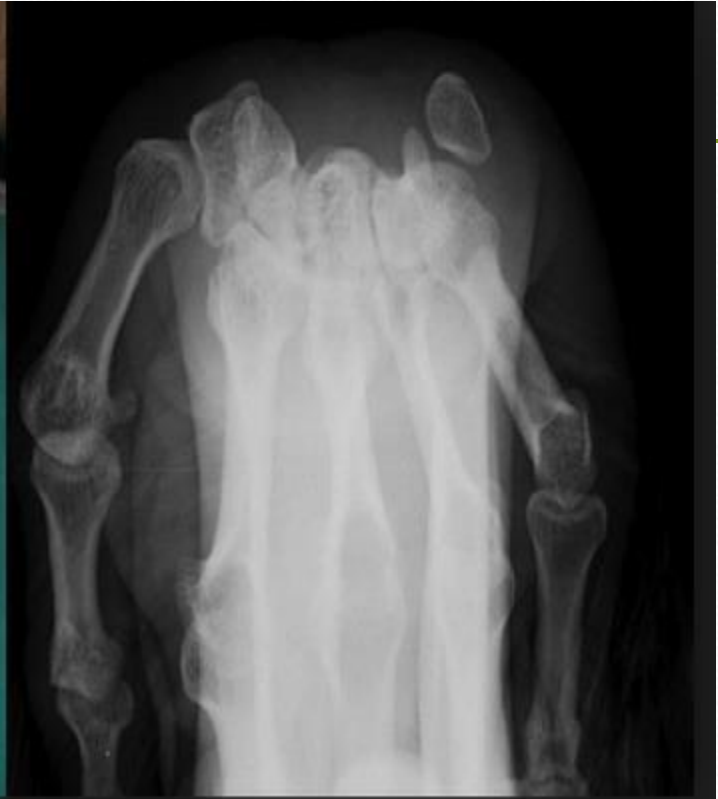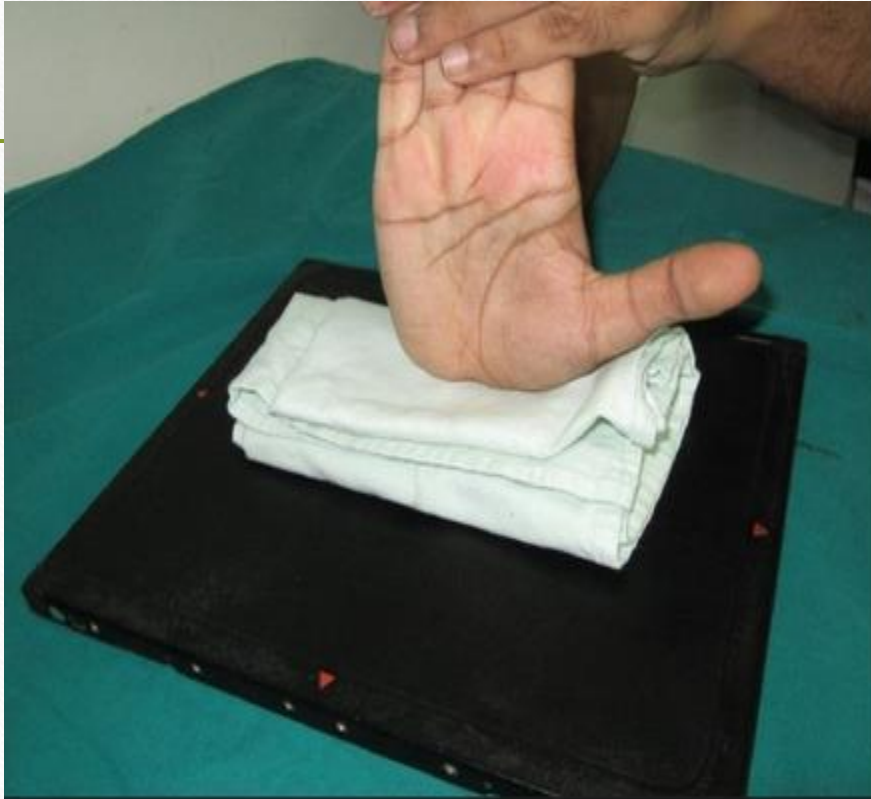# Exam













# Hook of Hamate Fracture

---

- Seen in golfers and baseball players
- Physical Exam:
  - TTP of the hamate bone in the hypothenar eminence
  - Decreased grip strength
  - Hook of hamate pull test: hand held in ulnar deviation as patient flexes DIP joints of 4<sup>th</sup> and 5<sup>th</sup> digits
- Treatment
  - Splint (short arm splint)
  - Surgical Removal (quicker return to play)

# References

---

- <https://www.orthobullets.com/trauma/1037/femoral-neck-fractures>
- <https://www.ncbi.nlm.nih.gov/pubmed/28759316>
- <https://www.orthobullets.com/foot-and-ankle/7029/high-ankle-sprain-and-syndesmosis-injury>
- <https://coreem.net/core/ankle-stress-views/>
- <https://www.ncbi.nlm.nih.gov/pmc/articles/PMC5639970/>
- <https://www.ncbi.nlm.nih.gov/pubmed/25536951>
- [https://www.rch.org.au/clinicalguide/guideline\\_index/Femoral\\_Nerve\\_Block/](https://www.rch.org.au/clinicalguide/guideline_index/Femoral_Nerve_Block/)